

High resolution manometry – an introduction

Mark Fox MD, MA (Oxon), MRCP

Specialist Registrar in Gastroenterology,

Oesophageal Laboratory,


St. Thomas' Hospital, London, SE1 7EH

Tel. +44 (207) 1884193 / 4

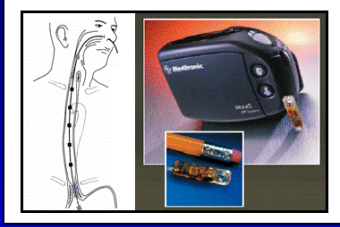
Email: markfox_2@hotmail.co.uk

The introduction of High Resolution Manometry at our institution was made possible by a generous grant from the Guy's and St. Thomas' Charitable Foundation. St. Thomas' Hospital is the first Oesophageal Laboratory in the United Kingdom to acquire HRM and the first in Europe to use the 36-channel solid state system from Sierra Systems. Although new in this country, HRM has replaced conventional manometry for routine clinical investigations in centres across the USA and is regarded as the new 'gold standard' in manometric investigation by prominent gastroenterologists including Ray Clouse, Peter Kahrilas, Gary Falk, Joel Richter and John Dent.

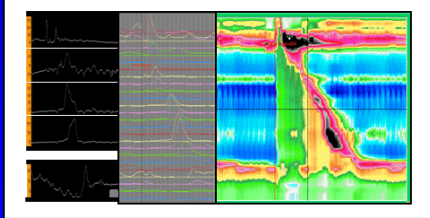
**St. Thomas' Hospital
Oesophageal Laboratory**




Catheter & Capsule pH Measurement



Conventional & High Resolution Manometry



Multi-channel intra-luminal impedance



Mark Fox 2005

High resolution manometry – an introduction

Oesophageal manometry with 5-8 pressure sensors is the conventional investigation for endoscopy-negative dysphagia and other functional oesophageal symptoms. Current classifications define oesophageal motor dysfunction in terms of a few basic patterns: abnormal sphincter relaxation, oesophageal spasm, hypertensive contractions, loss of tone and motility. This classification is simple, however the oesophagus comprises several anatomic segments which are affected by different neuro-functional influences, and the mechanics of bolus transport has been shown to be complex. The complex physiology of oesophageal function and the inability of conventional manometry to fully describe this complexity may explain why the cause of abnormal bolus transport and functional oesophageal symptoms remain uncertain in many patients despite full investigation.

High-resolution manometry (HRM) with one pressure sensor per centimeter from the pharynx to the stomach is a recent advance in oesophageal measurement, made possible by the development of miniaturised pressure sensors. Computer technology allows the large amount of data acquired by HRM to be analyzed and presented in real time either as conventional 'line' plots or as a 'spatiotemporal' plot (figure 1), a compact, visually intuitive display of oesophageal function. HRM plots are easy to use. On a superficial level users quickly learn to recognize normal and abnormal oesophageal function by pattern recognition. On a more profound level the ability to examine oesophageal function in detail and to measure pressure gradients provide objective information about the effects of motor activity on bolus transport.

The advantages of HRM have been described in a series of recent publications:

1. Closely spaced pressure channels provide detailed pressure information that reveals the segmental nature of oesophageal peristalsis. This is important because motor abnormalities can be limited to a short segment of the oesophagus and will be missed by pressure sensors spaced too far apart.^{1,2}
2. HRM increases the accuracy with which bolus transport can be predicted from manometry.¹ This is significant because abnormal bolus transport is a more important cause of oesophageal symptoms than manometric abnormalities *per se*.³ HRM identifies patients with poor coordination between the proximal and mid-oesophagus (wide 'transition zone'), focal hypotensive contractions or focal spasm that would be missed by conventional manometry. Crucially, HRM can distinguish between abnormalities that disturb bolus transport from abnormalities that have no effect on function (i.e. improves sensitivity *and* specificity of manometric investigation).¹

3. The measurement of pressure gradients within the oesophageal body and across the gastro-oesophageal junction (GOJ) provide an objective assessment of the forces that direct bolus transport.⁴ The clinical importance of this is illustrated by the finding that the pressure gradient across the GOJ has higher accuracy for the diagnosis of achalasia than conventional measurements of sphincter relaxation.⁵
4. HRM has been shown to increase diagnostic accuracy. In a group of 212 unselected clinical patients, Clouse and colleagues reported manometric disagreement in 12% between HRM and conventional manometry. Compared against 'final diagnosis' six months after the investigation, conventional manometry failed to identify several patients with achalasia and other causes of hypotensive and aperistaltic motility disorders. In only one patient was the HRM diagnosis changed at follow-up.⁶
5. Published case series supply vivid examples of clinically important pathology detected by HRM that was not provided (or not properly appreciated) by conventional investigation.
 - (i) The loss of coordination (wide 'transition zone') between the proximal (striated) and mid-distal (smooth muscle) oesophagus (figure 2)
 - (ii) Focal oesophageal spasm limited to the mid-oesophagus (figure 3)
 - (iii) Detection of an abnormal pressure gradient (i.e. resistance to flow) localizes pathology within the pharynx and upper oesophageal sphincter (e.g. cricopharyngeal bar).⁷
 - (iv) Functional (e.g. achalasia) resistance to bolus transport across the GOJ can be measured. Pseudo-relaxation of the lower oesophageal sphincter in vigorous achalasia is clearly seen (figure 4).
 - (v) Structural resistance to bolus transport caused by peptic stricture, extrinsic compression etc. can be identified on HRM (figure 5). This ability to differentiate the functional *and* structural anatomy of the GOJ greatly improves the ability to identify problems post-fundoplication.

HRM is simple to use and easy to learn for those with a basic knowledge of conventional manometry. The time consuming pull-through procedure is no longer required which speeds up the positioning of the catheter and significantly shortens the duration of the procedure. No sleeve sensor is required (an electronic 'virtual-sleeve' provides an identical recording if required). Movement and interaction of the intrinsic LOS and diaphragm is clearly seen, most dramatically in the presence of a hiatus hernia (figure 6). In patients with a weak or unstable LOS function, HRM greatly aids the placement of pH probes.⁶

In addition, HRM facilitates the detection of abnormal motor activity and in routine clinical studies analysis proceeds simultaneously with data acquisition. Even patients learn to recognize normal and abnormal swallows before the end of the investigation! Based on my experience of >400 clinical studies during the development of HRM in Switzerland, the technique provides a definitive diagnosis in the vast majority of patients referred for investigation of functional dysphagia in whom conventional manometry was non-diagnostic (10-20% overall, more in tertiary referrals). About half of these cases had focal abnormalities of peristalsis, the remainder LOS dysfunction. Increasing evidence suggests that HRM can detect specific abnormalities of oesophageal function that respond to specific medical treatments.⁸ Even when treatment is not available for pathology detected by HRM, an explanation of the symptoms prevented further investigation and inappropriate treatment, and was often therapeutic of itself.

In conclusion HRM has several advantages over conventional oesophageal manometry. Studies have shown that HRM identifies clinically important abnormalities of oesophageal function not detected by standard investigations and increases diagnostic accuracy. HRM helps physicians to work out the relationship between oesophageal motor function, abnormal bolus transport and the presence of symptoms. HRM is increasingly recognized as an important advance in the assessment of oesophageal function with real benefits in clinical practice.

References

1. Fox M, Hebbard G, Janiak P, et al. High-resolution manometry predicts the success of oesophageal bolus transport and identifies clinically important abnormalities not detected by conventional manometry. *Neurogastroenterol Motil* 2004;16:533-42.
2. Ghosh SK, Janiak P, Schwizer W, Hebbard GS, Brasseur JG. Physiology of the esophageal pressure transition zone: separate contraction waves above and below. *Am J Physiol Gastrointest Liver Physiol* 2006;290:G568-76.
3. Tutuian R, Castell DO. Combined multichannel intraluminal impedance and manometry clarifies esophageal function abnormalities: study in 350 patients. *Am J Gastroenterol* 2004;99:1011-9.
4. Ghosh SK, Pandolfino JE, Zhang Q, et al. Quantifying Esophageal Peristalsis with High-Resolution Manometry: a study of 75 asymptomatic volunteers. *Am J Physiol Gastrointest Liver Physiol* 2006.
5. Staiano A, Clouse RE. Detection of incomplete lower esophageal sphincter relaxation with conventional point-pressure sensors. *Am J Gastroenterol* 2001;96:3258-67.
6. Clouse RE, Staiano A, Alrakawi A, Haroian L. Application of topographical methods to clinical esophageal manometry. *Am J Gastroenterol* 2000;95:2720-30.
7. Williams RB, Pal A, Brasseur JG, Cook IJ. Space-time pressure structure of pharyngo-esophageal segment during swallowing. *Am J Physiol Gastrointest Liver Physiol* 2001;281:G1290-300.
8. Fox M, Fried M, Menne D, Stutz B, Schwizer W. The effect of tegaserod on oesophageal function: a randomized controlled trial *Gut* 2006 (in review).

Figure 1
Normal High Resolution Manometry (HRM)

HRM plot depicts the direction and force of oesophageal contraction from the pharynx to the stomach. The spatiotemporal plot (STP) presents the same information as the line plots, however the large volume of data is easier to appreciate as a single image. Time is on the x-axis and distance from the nose is on the y-axis. Each pressure is assigned a colour (legend adjacent to figure); colours can be adjusted to focus on different aspects of oesophageal function.

The normal physiology of oesophageal function is demonstrated including the synchronous relaxation of the upper and lower oesophageal sphincters, and the increasing pressure and duration of the peristaltic contraction as it passes distally. In addition subtle but functionally important pressure events are demonstrated clearly. The 'transition zone' (pressure trough) between the proximal and mid-oesophagus is visualized. Note the small 'common cavity' pressure rise after the water swallow that indicates filling of the oesophagus (the simultaneous increase in thoracic pressure after swallowing (blue to green)), followed by the steady increase in oesophageal pressure (green to orange) as peristalsis approaches the LOS. This represents the build up of pressure gradient that drives bolus transport from the oesophagus into the stomach.

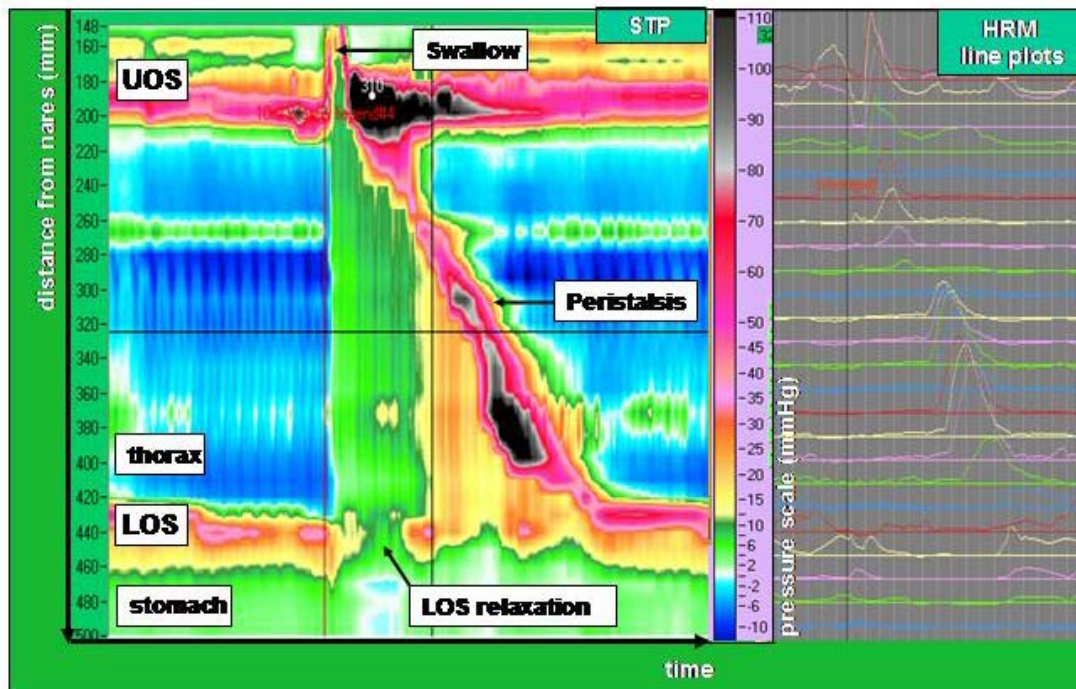


Figure 2

Loss of coordination between the proximal and mid-oesophagus

HRM from a patient with intermittent bolus impaction with solids. There is a wide transition zone (pressure trough) between the proximal (striated muscle) and mid-oesophagus (smooth muscle). Normal coordination between the proximal and distal oesophagus is lost. This abnormality can impair bolus transport through the oesophagus (as shown on concurrent videofluoroscopy).

This is a common finding in patients with functional dysphagia in whom conventional manometry is reported as normal. It is frequent in moderate to severe gastro-oesophageal reflux disease and appears to explain dysphagia and poor oesophageal clearance in those affected. Tegaserod (a 5-HT4 agonist similar to cisapride but without cardiac side effects) facilitates peristaltic contraction in the mid-oesophageal improving coordination between the two segments and thus promoting effective oesophageal clearance.⁸

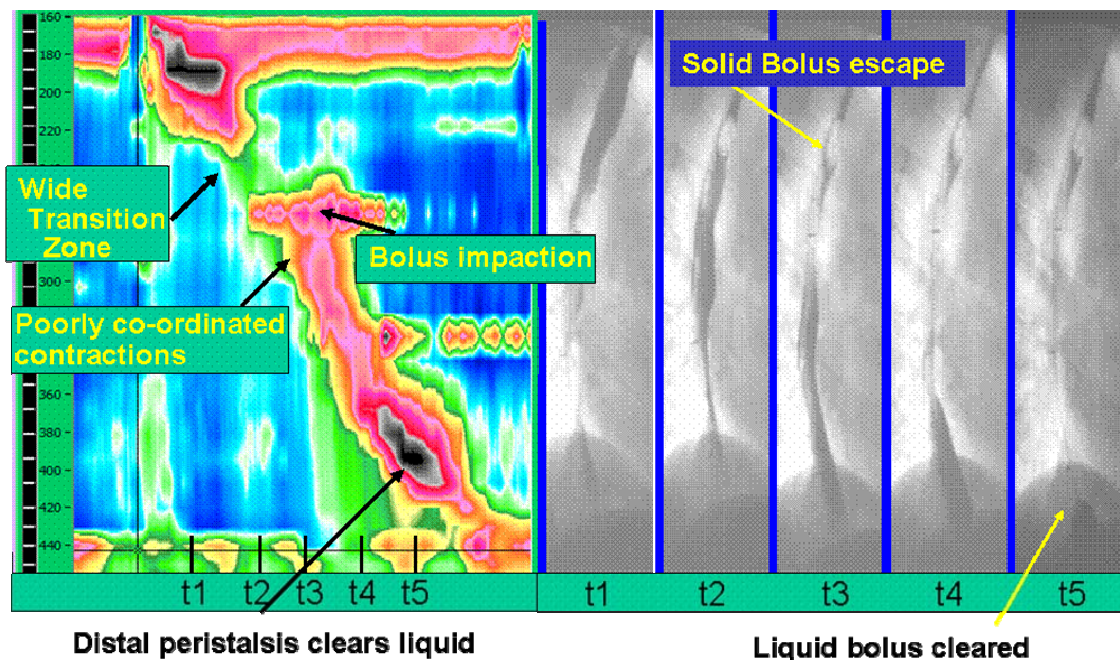


Figure 3
Focal oesophageal spasm

HRM from a patient with dysphagia, regurgitation and intermittent bolus impaction. There is a wide transition zone between the proximal and mid-distal oesophageal contractions. In addition there is focal spasm (simultaneous contraction) of the mid-oesophagus. Distal oesophageal function is normal.

This abnormality severely impaired bolus transport and was associated with odynophagia in this patient; however it was not seen on conventional manometry because the pathology was focal.¹ Nitrate donors slow peristalsis and corrected both the manometric abnormality and the symptoms. The patient was unable to tolerate ISMN (or similar medications), but responded well to sildenafil 25mg bd (Viagra).

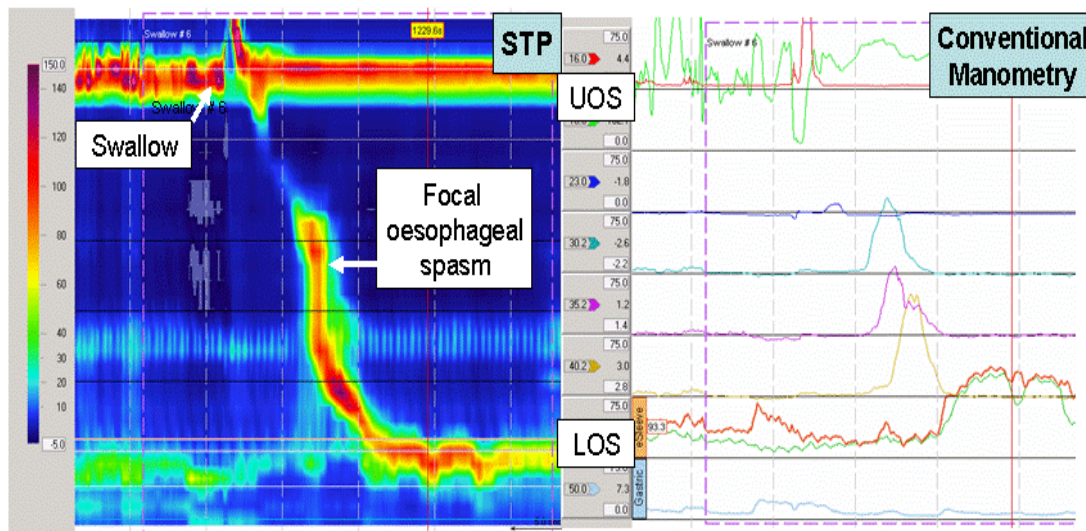


Figure 4
Classic Achalasia and Vigorous Achalasia

An example of classic achalasia recorded by HRM (above). The pharyngeal contraction is preserved; however the body of the oesophagus is aperistalsis and the lower oesophageal sphincter fails to relax. In addition intra-oesophageal pressure is higher than gastric pressure. HRM from a patient with dysphagia, regurgitation and chest pain on swallowing (below). LOS relaxation is absent and powerful oesophageal spasm causes marked shortening of the oesophageal body. The LOS appears to relax on the 'virtual sleeve' ('pseudo-relaxation') on swallowing because the 'sleeve' comes to lie in the stomach during oesophageal shortening. As a result on conventional manometry this patient was diagnosed with diffuse oesophageal spasm rather than vigorous achalasia and had not received appropriate treatment.

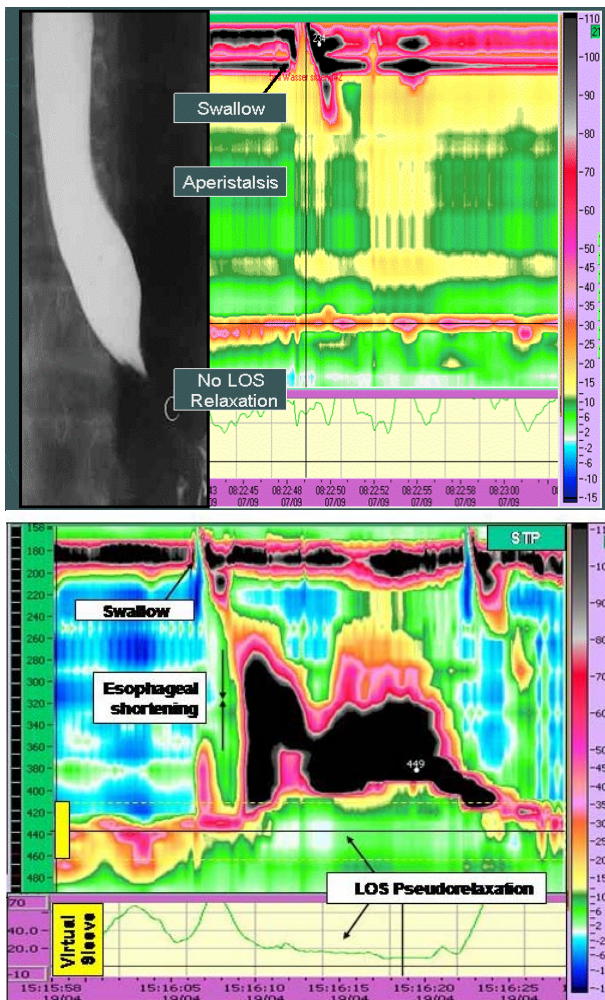


Figure 5

Resistance to flow caused by structural constriction at the LOS

HRM from a patient with intermittent dysphagia, regurgitation and chest pain on solid swallows. Endoscopy showed reflux oesophagitis above a large hiatus hernia. CT was essentially normal. The lower oesophageal sphincter was very weak above a large hiatus hernia. On swallowing liquids peristalsis was weak but no cause for dysphagia was seen. On swallowing a bread bolus peristaltic pressures increased and the pressure below the peristaltic wave (intra-bolus pressure) was abnormally high. This increased localized pressure gradient indicates resistance to flow at the level of the LOS. However, the LOS was weak and relaxed fully, thus a structural constriction must be present. Endoscopic ultrasound revealed a sub-mucosal malignant lesion at this level.

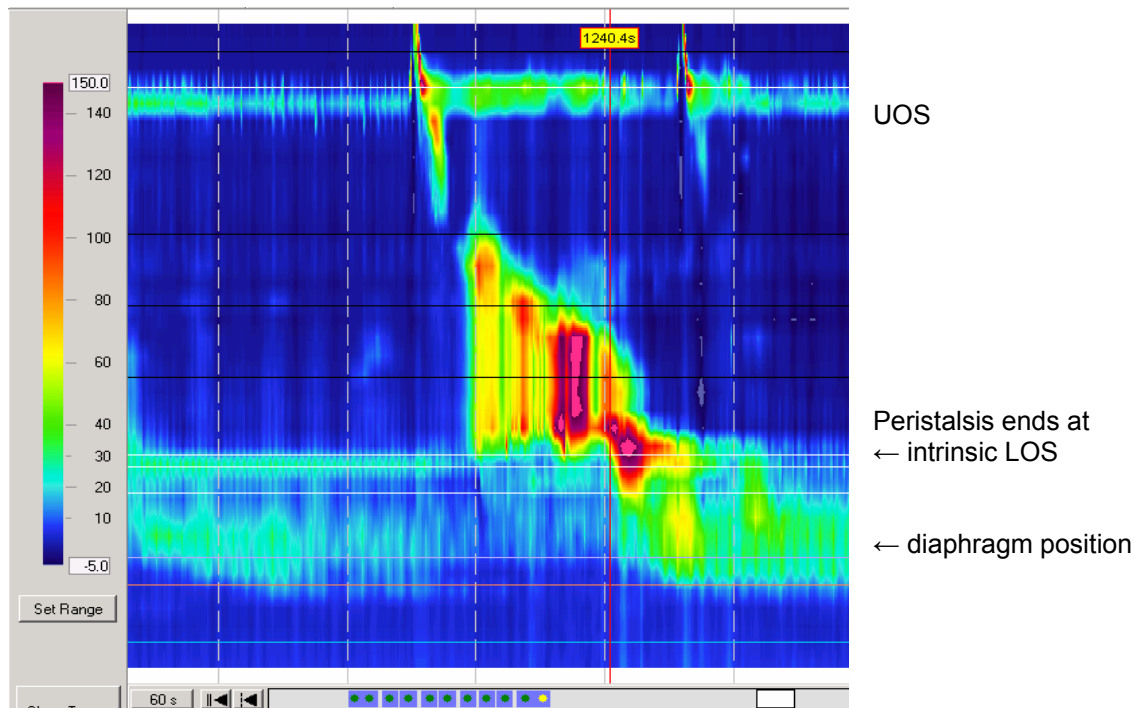
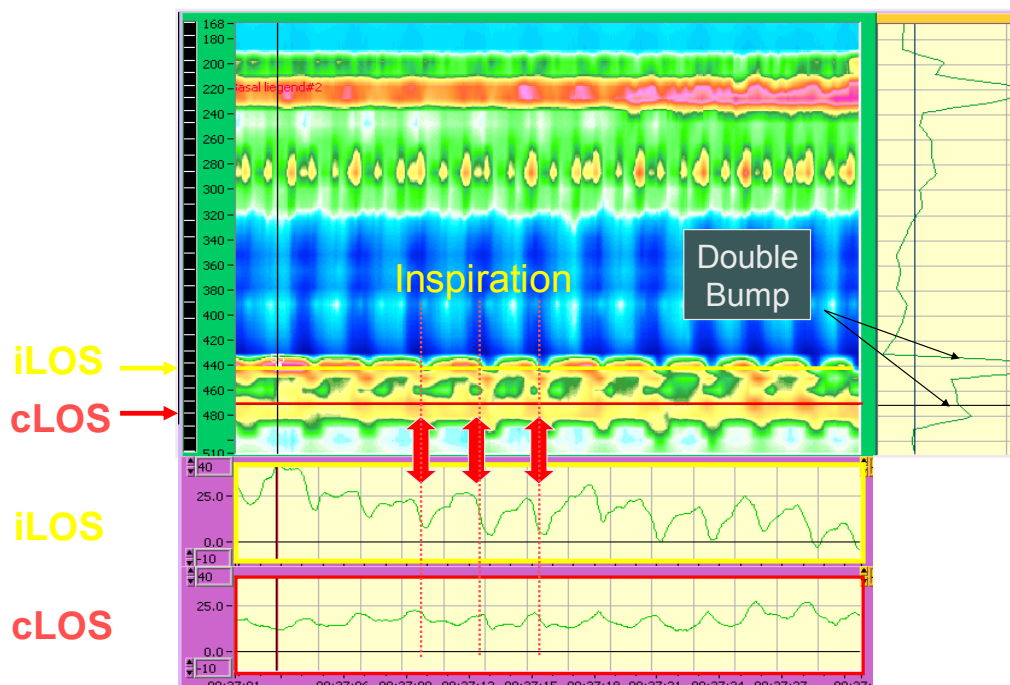


Figure 6
Hiatus hernia

HRM from a patient with typical symptoms of gastro-oesophageal reflux disease. The pressure measurements reveal that the LOS is divided into the proximal intrinsic LOS (iLOS) and distal diaphragmatic or crural LOS (cLOS). The 'double bump' of a hiatus hernia, as would be seen during a conventional 'pull-through', is seen when pressures along the y-axis of the cursor are displayed. Pressure along the x-axis placed at the level of the iLOS (yellow) and cLOS (red) are displayed in the box below; the complementary changes in pressure during inspiration and expiration are clearly demonstrated.



Note: Some figures were acquired using 36 channel solid state HRM (ManoScan 360, Sierra Systems), others using 32 channel water perfused HRM (Custom made, Advanced Manometry Systems). Data acquired by both systems is identical. The display differs only in details. However, only the solid-state equipment is commercially available and practical for routine clinical use.